

## A new concept for the non-invasive treatment of Adolescent Idiopathic Scoliosis: The Corrective Movement<sup>®</sup> principle integrated in the SpineCor System

CHRISTINE COILLARD, ALIN CIRCO & CHARLES H. RIVARD

*Ste-Justine Hospital, Montreal, Canada*

### Abstract

**Purpose.** To evaluate the change in spinal curvature and posture of Idiopathic Scoliosis patients when a curve specific 'Corrective Movement<sup>®</sup> Principle' (CMP) is applied.

**Methods.** This prospective interventional study was carried out on a group of 639 patients (92.3% females) having idiopathic scoliosis treated with the SpineCor brace. All girls were premenarchal or less than 1 year postmenarchal. Assessment of brace effectiveness followed the SRS outcome criteria for bracing. The clinical, radiological and postural evaluations assisted to define the patient classification, which guided the unique application of the CMP to each type of curvature.

**Results.** A total of 583 patients met the outcome criteria. Overall, 349 patients have a definitive outcome. Successful treatment was achieved in 259 (74.2%) of the 349 patients from the fitting to the weaning of the brace. Some 51 immature patients (14.6%) required surgical fusion while receiving treatment. Eight mature patients out of 298 (2.7%) required surgery within 2 years of follow-up beyond skeletal maturity.

**Conclusion.** The SpineCor brace is effective for the treatment of adolescent idiopathic scoliosis. Moreover, positive outcomes are maintained after 2 years because 151 (93.2%) of 162 patients stabilized or corrected their end of bracing Cobb angle up to 2 years after bracing.

**Keywords:** *Corrective movements, adolescent idiopathic scoliosis, conservative treatment effectiveness, SpineCor system, standardized outcome criteria*

### Introduction

The prevalence of Idiopathic Scoliosis (IS) is estimated to range from 2–4% of the population [1,2]. The principle characteristic of AIS is the torsion and deviation of the spine in the frontal plane which is accompanied by individual vertebral deformity [3] and disorientation [4]. In addition, the unique segmental specific vertebral morphology [5,6] and mobility, [6] as well as the risk factors such as growth [7] complicate the precise definition of the pathomechanics of disease progression and the definition of an optimal treatment approach.

There are several limitations of the current bracing techniques. These include the principle of the three-point pressure approach, which is the assumption that the same principle of force

application (amplitude and direction) can be used at different spinal levels. The efficacy of these forces that are applied through the bracing systems [8,9] has been questioned.

The unique morphology (skeletal and muscular) and mobility of each spinal level [6] suggests that a treatment approach that functions in accordance to these characteristics warrants further attention. Therefore a curve specific 'Corrective Movement<sup>®</sup> principle' (CMP) is proposed. A specific corrective movement is performed, and the brace is applied according to the SpineCor Assistant Software instructions. The moderate tension in the elastic bands allows the repetition and amplification of the corrective movements as the child undertakes everyday activities. This results in a progressive curve reduction. To obtain a neuro-muscular integration

of the new strategy of movement, the minimum duration of treatment is 24 months. Because of the progressive changes, absence of external support during the treatment and intact muscles, there is no loss of correction after the brace discontinuation.

The objective of this study is to describe the mechanisms that are behind this principle and quantify the induced change in spinal curvature and posture of Idiopathic Scoliosis patients when the 'Corrective Movement<sup>®</sup> principle' is applied followed by the fitting of the SpineCor brace.

### Material and methods

Each Idiopathic Scoliosis patient underwent a comprehensive evaluation. This included an anthropometrical, clinical, radiological and postural geometry examination. The anthropometrical evaluation involved the palpation of surface anatomical landmarks that served as markers for the clinical and postural geometry evaluations. The clinical exam involved both subjective observations of the patients posture (static and dynamic), as well as the evaluation of the history of the patient.

These evaluations served to define the amplitude and severity of the spinal curvature, the type of spinal curvature as well as additional postural characteristics unique to each type of curvature. This was followed by the definition and application on the patient of the curve specific 'Corrective Movement<sup>®</sup> principle' (CMP) (Figure 1) by the attending physician. The SpineCor brace was used to favour the CMP on the patient. (Figure 2) This non-rigid brace is composed of a pelvis base and a bolero fitted to the upper trunk as an anchor to manipulate the orientation of the pelvis, thorax and shoulders through the use of four elastic bands. The brace was fitted to favour the CMP in order to evaluate the induced changes on the spine and posture.

### The Corrective Movement<sup>®</sup> Principle (CMP)

The CMP evaluated in this study is based on the unique kinematics of the thoracic, thoracolumbar and lumbar segments of the spine. The amplitude and direction of these kinematics is defined by the shape of the vertebra, the geometry of its articular facets, the spinous processes and the presence or absence of rib articulations. Soft tissues such as muscles and ligaments also control, and limit actively or passively, the amplitude of the movement depending on the orientation of their vector of origin and insertion.

The mobility of the thoracic spine, from T1 down to T11, is directed not only by the orientation of the zygapophyseal facets in the frontal plane, but also by its articulation with the ribs, and muscle action. The

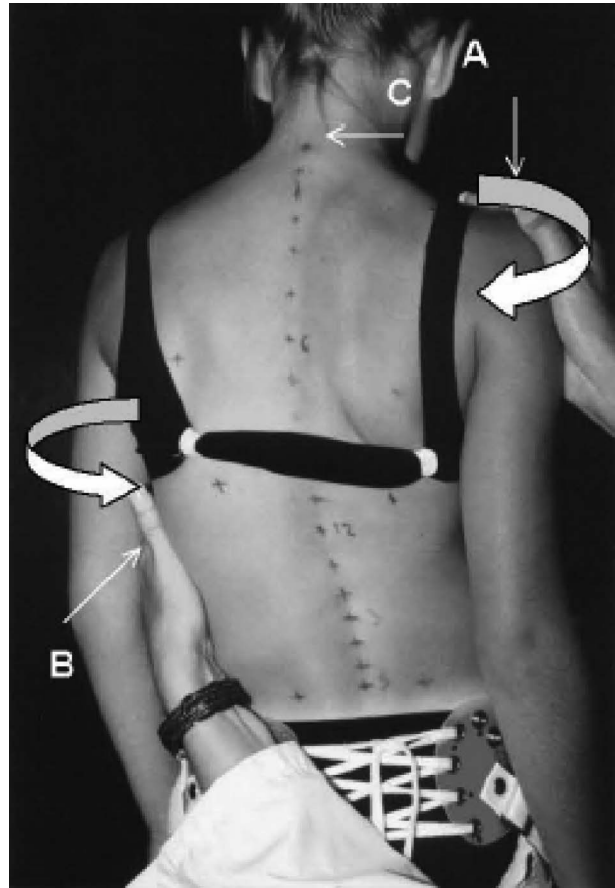


Figure 1. Corrective Movement<sup>®</sup> principle demonstrated on a right thoracic patient.

thoracic segment shows relatively important segmental motion in the transverse plane, with small amplitudes of flexion/extension [6]. In the thoracolumbar region, the joints with the rib cage are less constraining and the orientations of the facets are directed progressively in a sagittal direction. As a result, this segment could produce large movements in the frontal plane, some coupled movements in the sagittal plane, but very little in the transverse plane.

The shape of the lumbar vertebrae is very specific with facets in a complete sagittal plane. This segment could produce very large amplitudes of flexion/extension but little lateral bending and almost no rotation.

Since the movement amplitude of the thoracic spine is larger in torsion, the corrective movement should also be planned to occur in this direction. The correction of a right thoracic curve should then include a de-torsion of the thorax relative to the shoulder girdle (Figure 1). The shoulder girdle should be rotated to a neutral position or, if possible, progressively into a clockwise rotation. The corrective movement is then obtained by rotating the thorax in a counter-clockwise direction relative to the

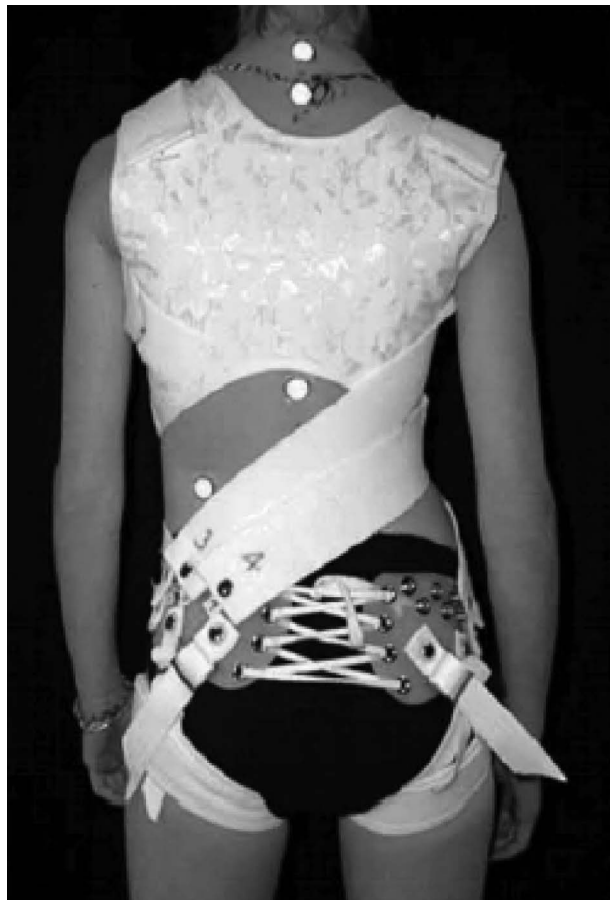

Figure 2. The Corrective Movement<sup>®</sup> principle promoted by the SpineCor system.

shoulders (A, B). This action will also prevent the shoulder rotation from being absorbed by the thoracolumbar or lumbar segment of the spine. This movement represents a de-torsion between the vertebral segments over and under the apex, associated with coupled movements in the frontal and sagittal plane. They then reach an improved alignment with the vertebrae involved in the scoliosis. The corrective movement is also accomplished with a slight down tilt of the right shoulder (A). The right lateral shift of T 1 in relation to SI should consequently be reduced (C). This combination of movements should result in the straightening of the spine.

In the thoracolumbar region (T11, T12 and L1), the movement of greater amplitude is the lateral bending. Thus the corrective movement includes a change in the bending of the trunk in the frontal plane. For a left thoracolumbar curve, it goes from a clockwise to a counter-clockwise bending of the trunk in reference to the pelvis. The right thoracolumbar curves require the opposite movement. To account for the frequent pelvis tilt of these patients, the use of a shoe lift should also be considered. This

horizontalisation of SI will then accentuate the desired action of the corrective movement in the frontal plane.

In the lumbar region under L1, the main permissible movement is the flexion/extension in the sagittal plane. However, this action is also closely associated with the natural 'C' shape configuration of the natural lordosis. However, its close location relative with the pelvis that represents a strong base should allow some alternative strategy. The corrective movement is then designed principally to occur in the frontal and the sagittal plane. It includes a right shift of the trunk relative to the pelvis, combined with a lateral inclination of the trunk to the left. This produces an extension of the lumbar vertebrae by bringing them into the direction of their natural position.

Since the double curvatures cover all segments of the spine, a specific plane of mobility could not be used. For these patients, the corkscrew shape of the spine represents the geometry to change. In these cases, the principal corrective movement includes torsion of the shoulders relative to the pelvis around a longitudinal axis. This specific spine shape should not be seen as a combination of two curves. The kinematics involved is different and is reflected by a specific postural geometry.

### Radiological classification

The conventional classification of idiopathic scoliosis is based on a radiological evaluation in the P/A view and different types are identified according to the position of the apex without any consideration of the sagittal view. This classification provides only partial information even though scoliosis is known as a three-dimensional deformation of the spine associated with postural disorganization. When comparing X-rays among patients classified as the same, several differences in the morphological aspect of the curvature and other characteristics may be noted. Clinically, the differences in posture for these patients are obvious enough to reconsider if they are indeed of the same type of scoliosis. This has led to the development of subclasses of the conventional classification of scoliosis patients. A classification that reflects the three-dimensional deformation of the spine and the associated postural disorganization is therefore essential. Observation of specific parameters, by combining frontal and sagittal X-rays, in order to get the maximum 3D information is involved.

- Tilt/rotation/version for each vertebra;
- Tilt/rotation/version for the shoulder girdle/thorax/pelvic girdle;
- P/A and lateral shift;

- Modifications in the sagittal plane of the thoracic, thoracolumbar and lumbar segments
- Anteversion/retroversion/antepulsion/retropulsion.

### The SpineCor treatment

- The SpineCor<sup>®</sup> brace is worn for 20 hours per day. The 4-hours out of the brace period should be taken in two or more intervals during the least active part of the day. The brace must be worn while sleeping;
- The length of treatment will depend on the severity of the curve, age at start of treatment and its evolution, but it is always a minimum of 24 months for adolescent scoliosis. Juvenile cases require much longer treatment times;
- To optimize the dynamic effect of the brace, patients are encouraged to perform any type of sport wearing the brace (except for swimming);
- Patients may be suggested to undergo a specific SpineCor Physiotherapy Program in order to complement the action of the SpineCor brace;
- A shoe lift may be also prescribed at the time of brace supply. All shoe lifts should be sole and heel, not just heel, and must be worn during all activities.

#### *Inclusion criteria were as follows:*

- Idiopathic scoliosis diagnosis and radiological confirmation of absence of significant pathological malformation of the spine;
- Risser 0, 1, 2 or 3;
- Initial Cobb angle equal to or above 15°;
- Initial Cobb angle equal to or less than 40° in adolescent and 50° in juvenile;
- No prior treatment for scoliosis.

#### *Exclusion criteria were as follows:*

- Presence of a congenital malformation of the spine, spina bifida aperta or spondylolisthesis;
- Neuromuscular scoliosis;
- Postural scoliosis.

Skeletal maturity is considered when Risser 4 or more is reached. The United States grading system [10] for Risser sign was used in this study. Respecting the criteria mentioned above, we needed to exclude some patients from the actual study. This prospective interventional study was carried out on a group of 639 patients (92.3% females) having idiopathic scoliosis treated with the SpineCor brace. Some 583 patients respected the inclusion criteria, 234 (40.1%) did not complete the treatment by brace at the time of the analysis and 51 immature patients

required surgical fusion while receiving treatment, leading up to 298 patients who had reached skeletal maturity at the end of bracing. Out of this cohort of patients, 162 patients had 2 years and 69 patients had 5 years follow-up post-bracing.

### Results

The results of this prospective interventional study were partially presented at the SOSORT 2007 meeting in Boston. Some 349 patients had a definite outcome, 51 (14.6%) required surgical fusion while receiving treatment and 298 finished the treatment by brace. From the 298 patients, 279 girls and 19 males, had reached skeletal maturity at the end of bracing. The average age at initiation of brace ( $n = 298$ ) was  $12.8 \pm 1.9$  years (range 6.6–16.5). Patients wore the brace an average of  $2.4 \pm 1$  year with an average age at the time of brace discontinuation of 15.4 years. A total of 162 patients had 2 years and 69 patients had 5 years follow-up post-bracing. The evolution of the mean Cobb angle of these patients is shown in Table I.

#### **Assessment of brace effectiveness includes all of the following:**

(1) *Percentage of patients who have 5° or less curve progression and the percentage of patients who have 6° or more progression at skeletal maturity*

Some 137 patients (46.0%) out of 298 stabilized their Cobb angle ( $\pm 5^\circ$ ) at skeletal maturity at the end of bracing, 122 patients (40.9%) corrected their initial Cobb angle and 39 patients (13.1%) had 6° or more progression of their initial Cobb angle. Successful treatment, as defined above, was achieved in 86.9% of SpineCor brace patients.

With post-brace treatment follow-up observation (Table II), the treatment success rate at 2 years was 93.2% ( $n = 162$ ), comparing the end of bracing Cobb angle to the one at 2 years post-bracing. Some 133 patients out of 162 stabilized their Cobb angle and 18 patients still improved from the time the braces were discontinued up to 2 years follow-up. After 5 years post-bracing, success was achieved in 95.6% ( $n = 69$ ) of the time, comparing the Cobb angle at the end of bracing to the one after 5 years post-bracing.

(2) *Percentage of patient who have had surgery recommendation/undergone before skeletal maturity*

A total of 51 immature patients (14.6%) out of 349 who respected the inclusion criteria and who had a definite outcome (298 + 51), required surgical fusion while receiving treatment. The average curve magnitude at bracing in this particular group was



Table I. Average Cobb angles for all structural curves at various points during and after treatment by the SpineCor brace.

	SpineCor brace				
	Beginning of treatment*	In brace*	End of treatment*	2 years post-bracing <sup>†</sup>	5 years post-bracing <sup>‡</sup>
Mean Cobb angle (°)	26.3 ± 6.8	19.2 ± 11.1	22.9 ± 11.5	21.4 ± 12.0	17.9 ± 10.4
Number of patients (n)	298	298	298	162	69

\*298 patients who had completed the treatment by brace at skeletal maturity; <sup>†</sup>162 patients who had 2 years follow-up after the end of bracing; <sup>‡</sup>69 patients who had 5 years follow-up after the end of bracing.

Table II. Treatment success for each time group of patients.

Success of treatment with brace	n	Percentage of success (%)
Beginning–end of treatment*	298	86.9
End of treatment–2 years follow-up <sup>†</sup>	162	93.2
End of treatment–5 years follow-up <sup>‡</sup>	69	95.65

\*298 patients who had completed the treatment by brace at skeletal maturity; <sup>†</sup>162 patients who had 2 years follow-up after the end of bracing; <sup>‡</sup>69 patients who had 5 years follow-up after the end of bracing.

32.7° ± 6.1° (range: 17–41°). General indication for fusion in all patients was progression of primary curve of more than 60° in thoracic region and 45° in thoracolumbar and lumbar region.

### (3) Percentage of patients who progressed beyond 45° at maturity

Seven patients out of the 298 patients who had a definite outcome (2.3%) had documented progression of curve beyond 45° at maturity. Surgery was required for 3 of these patients.

### (4) 2-years follow-up beyond maturity to determine the percentage of patients who subsequently undergo surgery

Eight mature patients out of 298 (2.7%) require surgery after weaning of the brace.

### (5) Curve magnitude

To study the effect of curve magnitude on outcome.

## Discussion

The objective of this review was to evaluate the acute change of an adolescent Idiopathic Scoliotic curve and posture that may be induced by the application of the CMP and to perform an evaluation of the long-term outcome results of the prospective cohort of patients who completed the treatment with the SpineCor brace. Moreover, we wanted to compare the effectiveness of the SpineCor brace to rigid braces, particularly; Boston brace [11,12], Wilmington brace

[13], Milwaukee brace [14], Charleston brace [10,15] and the Rosenberger brace [16].

Within the context of this article the term CMP is used to define the manner in which this spinal change may be achieved. The Corrective Movement<sup>®</sup> principle involved inducing a change to the initial posture of the patient. The application of this movement is dependent upon the initial state of the patient, as well as the complex interaction of soft tissue, coupled vertebral movements and the morphological characteristics of each vertebra. The effectiveness of this movement does not necessarily imply the application of large external forces, but optimal forces applied in an optimal direction for each type of scoliosis curvature. When the patients were divided into groups according to the classification of idiopathic scoliosis, there were specific postural characteristics identified with each type of scoliosis curvature. The principal plane in which these characteristics were located was specific to each class of patient. This included the apical view for the thoracic and double curve patients, and the frontal view for the thoracolumbar and lumbar patients. The nature of these differences between each type of curve is principally related to the mobility of each spinal segment and the different muscular attachments and actions at each spinal level. The Corrective Movement<sup>®</sup> principle was conceived to function with respect to the unique skeletal morphology and muscular characteristics. When the patients were prescribed with the Corrective Movement<sup>®</sup> principle, and the spinal bracing system was fitted to induce this principle, there was a significant decrease in the degree of spinal curvature for all of the patients.

This change in spinal curvature was accompanied by a significant change in the patients' posture. These postural changes were specific to each type of scoliosis curve, reflecting the unique corrective movement sought after for each patient. For the thoracic patients these changes involved the opposite rotation of the shoulder girdle in reference to the thorax accompanied by a coupled movement of shoulder tilt and lateral shift of T1 in reference to SI. For the thoracolumbar patients there was also a change in the relative rotation of the shoulders in reference to the pelvis, the tilt of the shoulders and tilt of the shoulders in reference to the pelvis.

Although there were a relatively small number of lumbar patients, they showed a tendency for a tilt of the shoulders. The patients with a double curvature had a significant change of the shoulders in reference to the pelvis in the transverse plane. With these postural changes, it is important to note that there was not a realignment of the patients' posture to a completely normal position. Also, the in-brace posture was not consistent across all of the patients with a similar type of curvature, which underlines the unique degree of mobility for each patient. This indicates that the mechanism sought to correct the spinal deformity with the brace, is not a normalization process, but a postural change that will lead to a correction of the spine. It is also a mechanism that is dependant on, and specific to, the unique mobility of each spinal level, the flexibility of the patient's posture, and the adaptability of the musculoskeletal system.

To assess the effectiveness of a nonsurgical treatment of scoliosis, it is important to evaluate efficacy of bracing in patients who are at greatest risk of progression. All types of curves were treated with the SpineCor brace as well as both genders.

A previous study was published in 2007 in *Journal of Pediatric Orthopaedics* [17] on the first 493 patients from the same data bank used for this present study. The actual study expands upon this by taking in consideration standardized outcome criteria published by the SRS Committee in 2005 [18]. The preliminary study in 2007 revealed that on the 47 patients who had a minimum post-treatment follow-up of 2 years, 10.7% continued the correction of their initial Cobb angle even after the weaning of the brace, 85% stabilized their Cobb angle and only 4.3% worsened by more than 5° (that represents a total of 95.7% of success). The recent results go in a similar direction. Indeed, this study reveals that the orthopedic treatment was a success for 93.2% of the 162 patients having a minimal post-bracing follow-up of 2 years, comparing the end of bracing Cobb angle to the one at 2 years post-bracing. Of these, 18 patients (11.1%) corrected their Cobb angle and 133 patients (82.1%) had stabilization. As reported by Montgomery and collaborators [19], a follow-up of 2 years is sufficient to foresee progression after weaning from the brace. The results are even more encouraging if we look in the long term. There are 69 patients who now have 5 years post-treatment follow-up. Permanent correction was achieved in 28.9% of the cases (20 patients), stabilization in 66.6% (46 patients) and only 4.4% (three patients) progression of the curve, comparing the end of bracing Cobb angle to the one at 5 years post-bracing. Finally, success was achieved for 95.6% of the 69 patients having a post-bracing follow-up of 5 years,

comparing the end of bracing Cobb angle to the one at 5 years post-bracing. These data suggest it is possible to maintain in the long term, the correction or stabilization obtained during the treatment by brace.

Although earlier reports indicated that the Milwaukee brace [20] could afford some lasting reduction in the degree of spinal curvature, subsequent studies with longer follow-up demonstrated that, following the cessation of brace treatment, curves that had demonstrated some correction at the end of bracing with classical rigid braces tended to continually increased toward the pre-treatment magnitude [11,13,14,21]. In the study of Noonan and colleagues [14], 63% of the 88 patients wearing the Milwaukee brace were classified as a failure. They defined three types of failure: (i) Increased 5° or more from initial bracing to the time that the patient stop wearing the brace, (ii) underwent a surgery or had a structural curve of more than 50° at the time of the follow-up, and (iii) major curve progressed 10° or more from initial bracing to time to follow-up. Noonan et al shown that 27 patients (31%) had an arthrodesis; of these 18 patients (67%) had curve progression while they wore the brace, and 9 (33%) had progression of the curve after a trial of intentional weaning. We notice this lost of correction over-time with other braces such as Wilmington and Boston braces. In the study by Gabos et al. [13], 22% out of 55 patients demonstrated an increased in the curve of  $\geq 5^\circ$  between the end of bracing with the Wilmington brace and the time of final follow-up (mean of 14.6 years after the completion of treatment). Besides, 13% demonstrated an increase in the curve of  $\geq 5^\circ$  between the end of bracing and the time of final follow-up that resulted in a curve that was  $\geq 5^\circ$  greater than the deformity measured at the time of the initial treatment. Katz and Durrani [11] conducted a retrospective study on 51 patients with AIS treated with the Boston brace for curve ranging between 36° and 45°. At the time of brace discontinuation, 31 patients (61%) were judged treatment success. With follow-up observation, an additional eight patients progressed beyond 5°, and a total of 16 patients (31%) required surgical correction. Olafsson et al. [12] studied a population of AIS patients wearing the Boston but with smaller curves (22–44° curve magnitude). They used two types of Boston braces, first one with 0° lumbar profiles and the other one with 15° lumbar profile. A total of 50 patients completed treatment with the 0° lumbar profile brace. For this cohort of patients, mean Cobb angle at treatment start was  $32 \pm 6^\circ$ , after bracing was  $12.1 \pm 7.6^\circ$ , after weaning  $25.4 \pm 11.3^\circ$  and at follow-up  $29 \pm 12^\circ$ . Regarding the 60 patients still in treatment wearing the Boston brace with 15° lumbar

profile, in one third of the case, either it remained unchanged or it increased with bracing. However, our results show that it is possible to obtain a correction of the pretreatment Cobb angle and this correction can be maintained 2 years, and even 5 years, after the end of the treatment by SpineCor brace. Actually, for the cohort of patients with 5 years post-bracing follow-up (69 patients), comparing the Cobb angle at the end of bracing to the one after 5 years follow-up, 20 patients (28.9%) still corrected their curvature, 46 patients stabilized their Cobb angle and their was only 4.4% of worsening (three patients). With the Dynamic SpineCor brace there is no component of collapse after the end of bracing, as noted for rigid braces [13,14,21] which, by not supporting an effective musculature, may encourage the progressive collapse of the curves [22].

The purpose of any conservative treatment for AIS is to alter the natural progression of the spinal deformity. It has been shown that patients with Risser 0 or 1 have 68% incidence of progression [21]. So if we compare our results of brace treatment with the natural history of AIS, we can assume that SpineCor is efficient to alter the natural history of this pathology. Effectively, the overall success rate of 86.9% with the brace indicates that the SpineCor brace does significantly modify the predicted natural history of the disorder. If we compare our results to the ones found in the literatures, we can appreciate the positive outcome of SpineCor patients. The first published study on the clinical effectiveness of the Rosenberger brace [16] demonstrated an overall failure rate similar to untreated rates from published natural history studies. Some 61% out of 71 patients worsened their Cobb angle; 40 curves (56%) progressed more than 5°, 22 patients (31%) either had the surgery or met surgical criteria, and 10 patients (14%) who did not have surgery progressed greater than 10°. Trivedi and Thomson [15] had an overall success rate of 60% with the Charleston brace. On the other hand, Gepstein et al. [10] achieved 80% of success (population of 85 patients) with the Charleston brace. In this study, surgery was performed in 11.8% of patients. Trivedi and Thomson only included girls in their study creating an element of selection bias, since boys seem to have more severe curves than girls [11,15]. Surprisingly, they still got the poorest results even if they excluded boys compared to the study by Gepstein and co-workers [23].

In summary, the SpineCor Brace is effective for the treatment of AIS. Moreover, the positive outcome appears to be maintained in the long term. This particular finding about the SpineCor brace appears to make it very different from the classical rigid braces in which any apparent correction obtained during treatment can be expected to be

lost over time, i.e., after the cessation of bracing [13,21]. However, futures studies to support this finding are necessary. Upcoming studies respecting the same standardized outcome criteria for AIS brace studies as used in this actual study will allow valid and reliable comparison between the SpineCor brace and any others rigid braces.

## References

1. Bunnell WP. The natural history of idiopathic scoliosis. *Clin Orthop* 1988;229:20–25.
2. Weinstein S. Natural history. *Spine* 1999;24(24):2592–2600.
3. Wever DJ, Veldhuizen AG, Klein JP, Webb PJ, Nijenbanning G, Cool JC, v Horn JR. A Biomechanical analysis of the vertebral and rib deformities in structural scoliosis. *Eur Spine J* 1999;8(4):252–260.
4. Sevastik B, Xiong B, Sevastik J, Hedlund R, Suliman I. Vertebral rotation and pedicle length asymmetry in the normal adult spine. *Eur Spine J* 1995;4(2):95–97.
5. Moore KL. Clinically orientated anatomy. 2nd ed. Baltimore: Williams & Wilkins; 1985.
6. White AW, Panjabi M. Clinical biomechanics of the spine. New York: J.B Lippincott Company; 1990.
7. Guillaumat M, Lebard JP, Khouri N, Tassin JL. Scoliose Idioapthique en période de croissance. *Appareil Locomoteur*; 1991.
8. Aubin CE, Labelle H, Ruszkowski A, Petit Y, Gignac D, Joncas J, Dansereau J. Variability of strap tension in brace treatment for adolescent idiopathic scoliosis. *Spine* 1999; 24(4):349–354.
9. Aubin CE, Dansereau J, de Guise JA, Labelle H. Rib cage-spine coupling patterns involved in brace treatment of adolescent idiopathic scoliosis. *Spine* 1997;22(6):629–635.
10. Gepstein R, Leitner Y, Zohar E, Angel I, Shabat S, Pekarsky I, Friesem T, Folman Y, Katz A, Fredman B. Effectiveness of the Charleston bending brace in the treatment of single-curve idiopathic scoliosis. *J Pediatr Orthop* 2002;22:84–87.
11. Katz DE, Durrani AA. Factors that influence outcome in bracing large curves in patients with adolescent idiopathic scoliosis. *Spine* 2001;26:2354–2361.
12. Olafsson Y, Saraste H, Soderlund V, Hoffsten M. Boston brace in the treatment of idiopathic scoliosis. *J Pediatr Orthop* 1995;15:524–527.
13. Gabos PG, Bojescul JA, Bowen JR, Keeler K, Rich L. Long-term follow-up of female patients with idiopathic scoliosis treated with the Wilmington orthosis. *J Bone Joint Surg Am* 2004;86-A:1891–1899.
14. Noonan KJ, Weinstein SL, Jacobson WC, Dolan LA. Use of the Milwaukee brace for progressive idiopathic scoliosis. *J Bone Joint Surg Am* 1996;78:557–567.
15. Trivedi JM, Thomson JD. Results of Charleston bracing in skeletally immature patients with idiopathic scoliosis. *J Pediatr Orthop* 2001;21:277–280.
16. Spoonamore MJ, Dolan LA, Weinstein SL. Use of the Rosenberger brace in the treatment of progressive adolescent idiopathic scoliosis. *Spine* 2004;29:1458–1464.
17. Coillard C, Vachon V, Circo A, Beausejour M, Rivard CH. Effectiveness of the SpineCor brace based on the new standardized criteria proposed by the Scoliosis Research Society for Adolescent Idiopathic Scoliosis. *J Pediatr Orthop* 2007;27:375–379.
18. Richards BS, Bernstein RM, D'Amato CR, Thompson GH. Standardization of criteria for adolescent idiopathic scoliosis brace studies: SRS Committee on Bracing and Nonoperative Management. *Spine* 2005;30: 2068–2075.

19. Montgomery F, Willner S, Appelgren G. Long-term follow-up of patients with adolescent idiopathic scoliosis treated conservatively: An analysis of the clinical value of progression. *J Pediatr Orthop* 1990;10:48–52.
20. Edmonsson AS, Morris JT. Follow-up study of Milwaukee brace treatment in patients with idiopathic scoliosis. *Clin Orthop Relat Res* 1977:58–61.
21. Bassett GS, Bunnell WP, MacEwen GD. Treatment of idiopathic scoliosis with the Wilmington brace. Results in patients with a 20–39 degree curve. *J Bone Joint Surg Am* 1986;68:602–605.
22. Coillard C, Leroux MA, Zabjek KF, Rivard CH. SpineCor non-rigid brace for the treatment of idiopathic scoliosis: Post-treatment results. *Eur Spine J* 2003;12:141–148.
23. Ponseti IV, Friedman B. Prognosis in idiopathic scoliosis. *J Bone Joint Surg Am* 1950;32A(2):381–395.